

# Effect of Bacterial Fluorescence Imaging on Patient Care and Wound Management in a Hospital Setting: A Pilot Study



Rosemary Hill, BSN CWOCN CETN(C)<sup>1</sup> and Joshua Douglas, MD, FRCPC, ABIM<sup>2</sup>

<sup>2</sup>Infectious Disease and Critical Care Internal Medicine, <sup>1,2</sup>Lions Gate Hospital, Vancouver Coastal Health, North Vancouver, BC, Canada

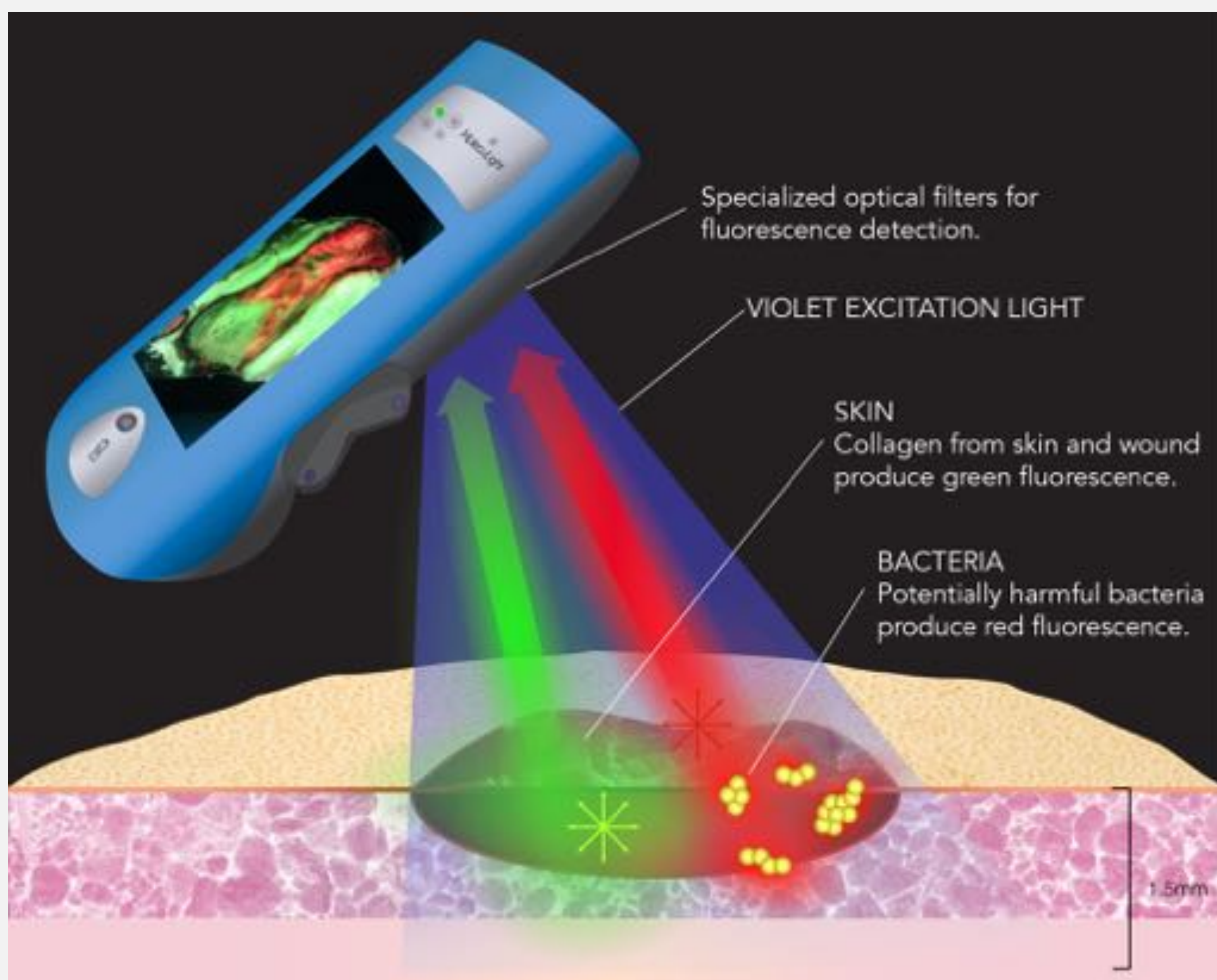
## INTRODUCTION

- Chronic wounds requiring hospitalization often harbor a high bacterial burden that negatively impacts tissue healing<sup>1</sup>.
- Knowledge of a wound's bioburden is currently obtained via culture analysis of wound swabs. This knowledge greatly impacts clinician treatment decisions. However, 24-48 hours can pass before results are available and false negative rates are high.
- Real-time, point-of-care detection of critical levels of bioburden relies primarily on visual inspection of wounds and clinical signs and symptoms, which are subjective and suboptimal.
- To address this problem, fluorescence imaging has been used to visualize red-fluorescing, pathogenic bacteria in real-time at the bedside using a non-contact hand held device<sup>2-3</sup>.
- This 7-week pilot study aimed to assess the effects of bacterial fluorescence images on clinician decisions and patient care

## METHODS

### Bacterial Fluorescence Imaging (MolecuLight i:X)

- When excited by 405 nm violet light, tissues fluoresce green while bacteria fluoresce red (porphyrin-producers, e.g. *Staphylococcus aureus*) or cyan (pyoverdine-producing *Pseudomonas aeruginosa*).
- This enables real-time, point-of-care detection and localization of bioburden within and around wounds<sup>2-4</sup>.

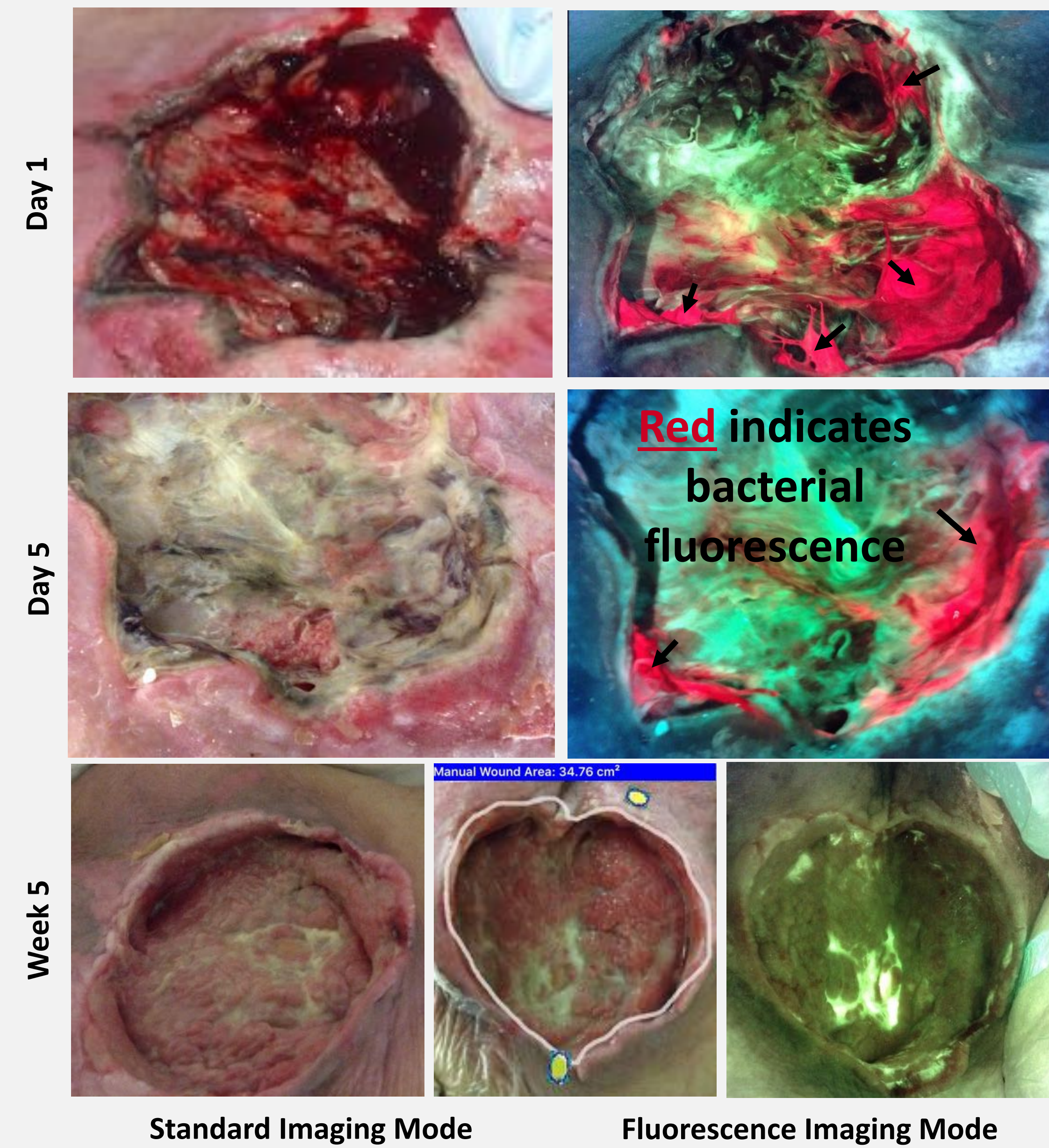


### Pilot Study

- 40 wounds with diverse etiologies were imaged with the fluorescence imaging device at various stages of the wound healing process. 6 cases (3 bacterial fluorescence positive, 3 bacterial fluorescence negative) are presented here and the effects on treatment decisions and patient care described.
- Wounds that were positive for red or cyan fluorescence signal were considered to have clinically significant bacterial loads. This real-time information guided immediate treatment decisions.
- All instances of bacterial fluorescence were confirmed via swab cultures. **All cultured regions of bacterial fluorescence exhibited moderate to heavy pathogenic bacterial growth.**

## RESULTS

### Bacterial Fluorescence Guides Debridement, Sampling, and Treatment Selection

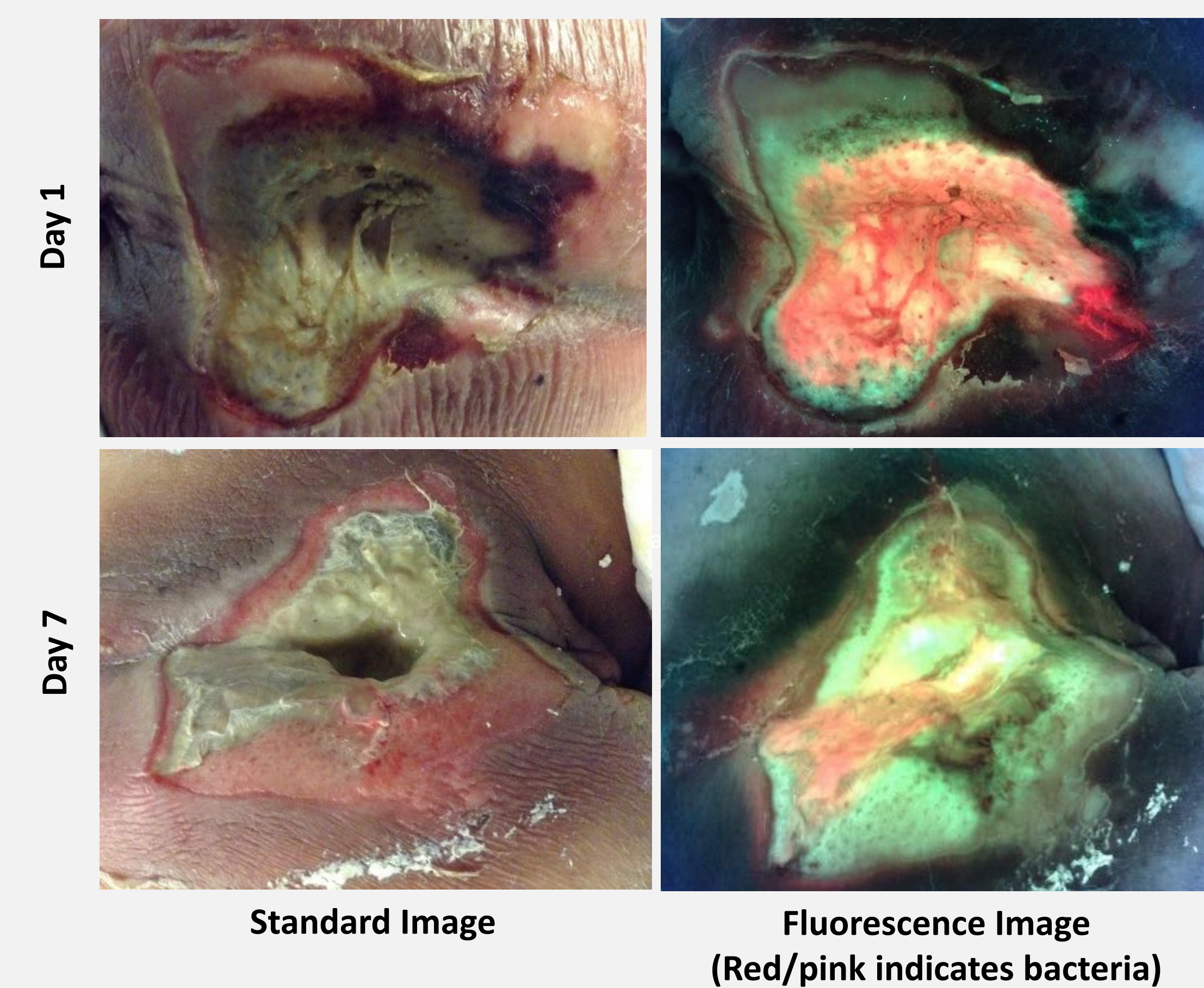


83-year-old male with septic sacral ulcer, diminishing mobility, and minimal at-home care. Fluorescence images taken post debridement revealed extensive remaining bioburden. Images immediately guided swabbing location and maintenance on IV antibiotics. Images also guided additional, targeted debridement (sparing non-contaminated regions) on day 5. Images acquired at each subsequent dressing change tracked significant decreases in bioburden and wound size (see week 5 images).

Swabs confirmed heavy growth of *Morganella morganii*, *E. coli*, and *Enterococcus faecalis*.

### Bacterial Fluorescence Prevents Discharge of Patients Requiring Systemic Antibiotics

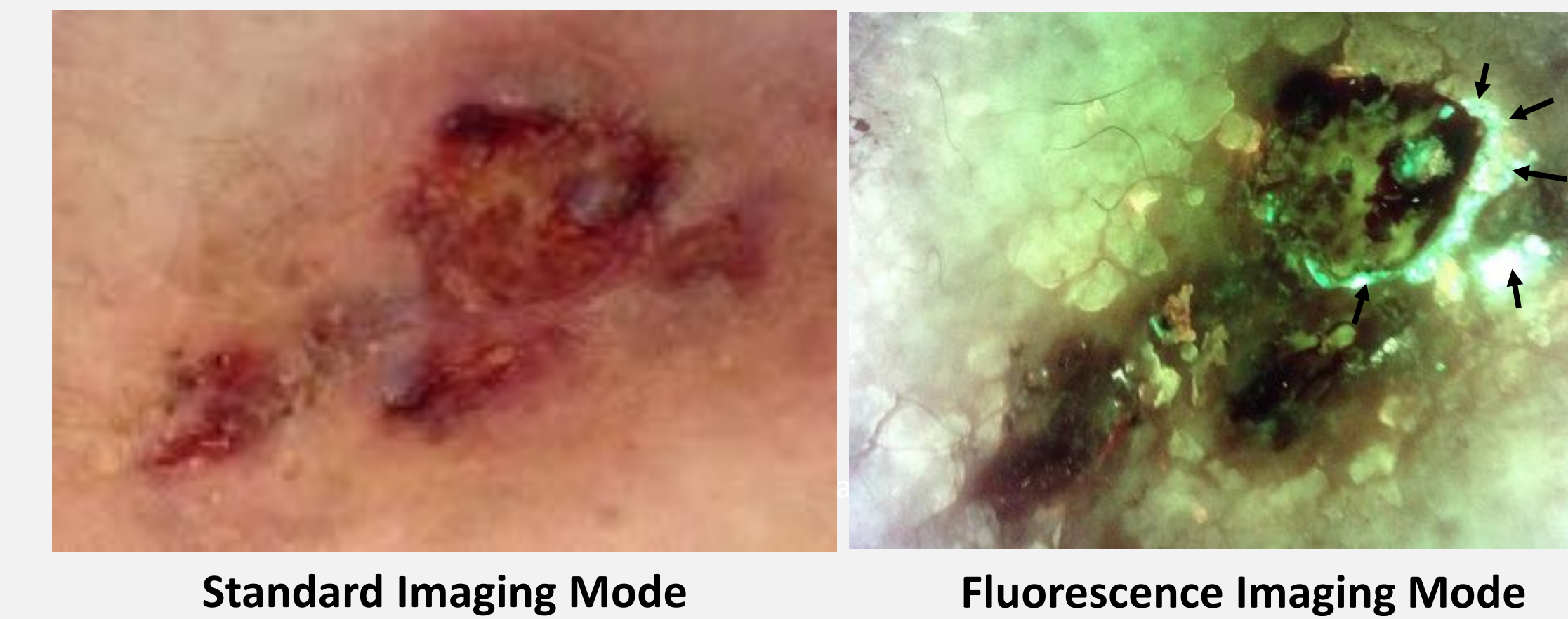
During this 7-week trial, images with extensive bacterial fluorescence prevented imminent discharge of 3 patients requiring systemic antibiotics.



63-year-old female lymphoma patient presented in outpatient chemotherapy unit for follow up; sacral ulcer revealed. Unit intended to discharge patient home, until bacterial fluorescence images documented significant bioburden, leading to hospitalization and systemic antibiotics.

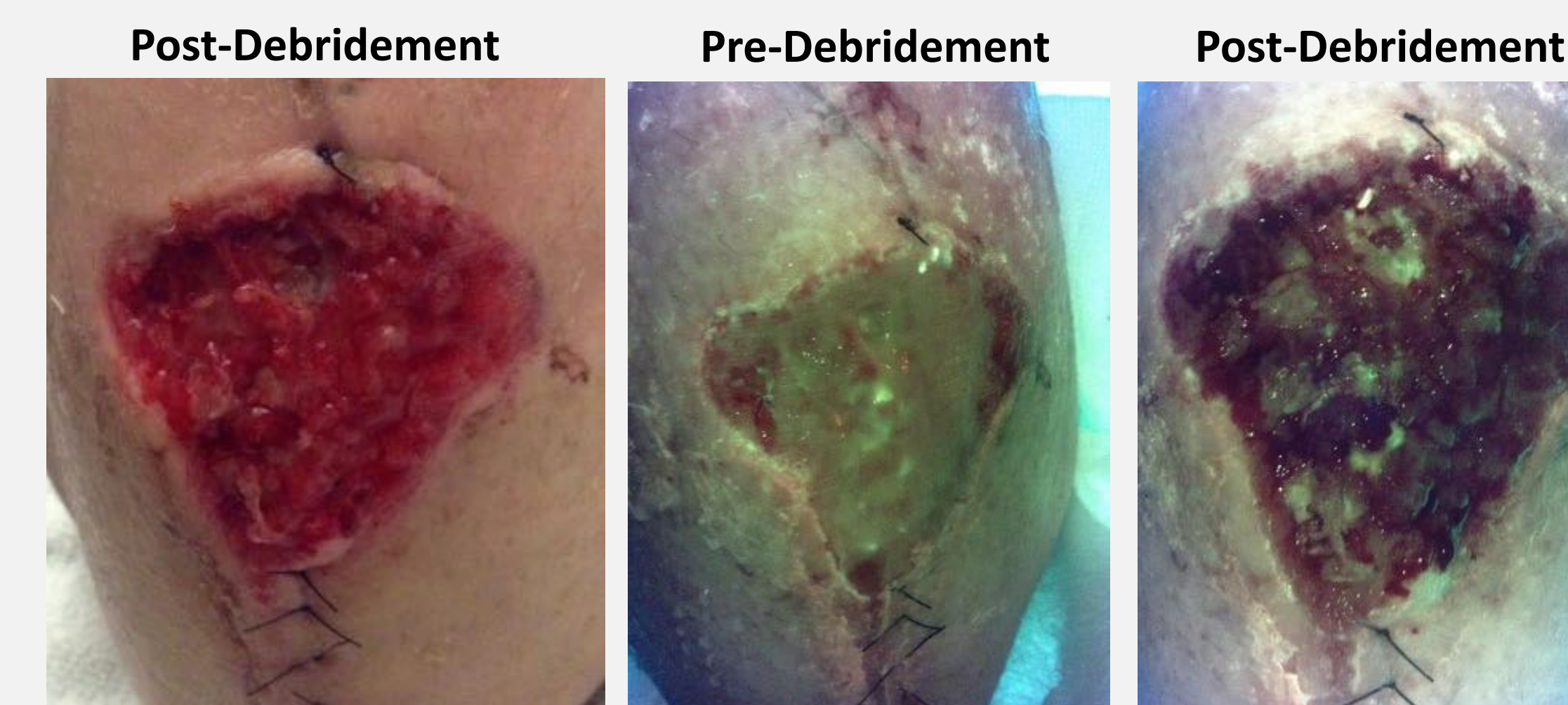
Swabs confirmed heavy growth of *Staphylococcus aureus* and *E. coli*.

### Bacterial Fluorescence Targets Swabbing to Region of Bioburden, Identifies Asymptomatic *Pseudomonas*



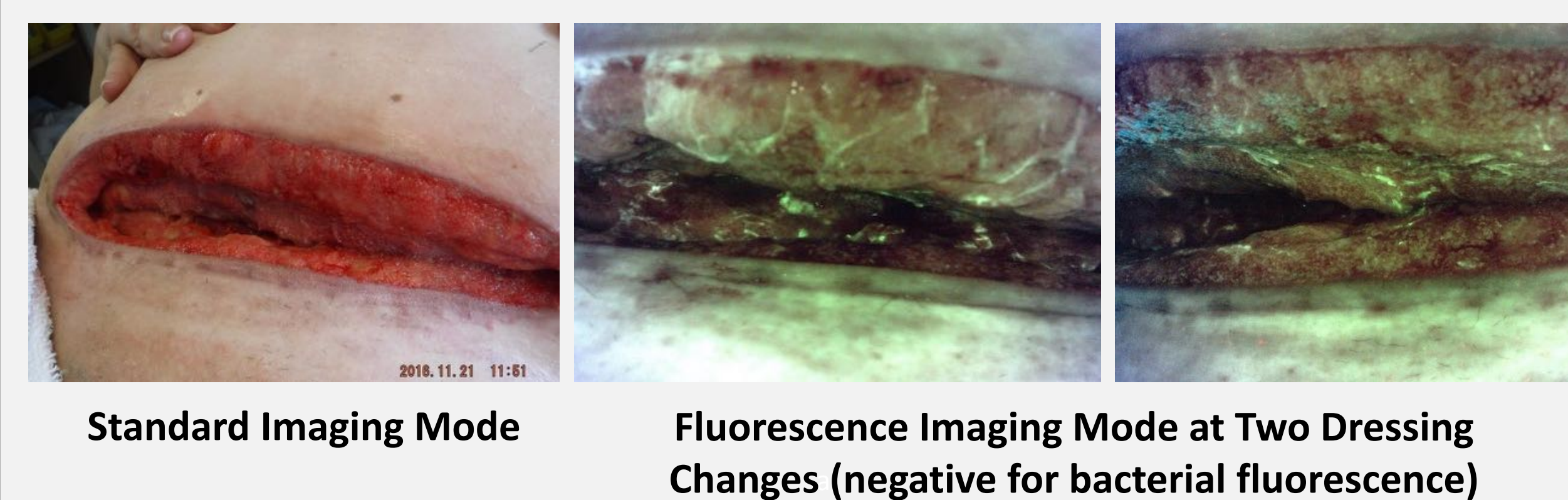
74-year-old female with VLU was referred to wound specialist for stalled healing. Patient had previously received multiple courses of systemic antibiotics, with no effect. **Wound had no clinical signs and symptoms of *Pseudomonas aeruginosa*, yet fluorescence images revealed its signature cyan fluorescence (arrows).** A *Pseudomonas*-targeted dressing was therefore selected which was effective; no further systemic antibiotics were required. Swabs of cyan region confirmed moderate growth of *Pseudomonas aeruginosa*.

### Images Negative for Bacterial Fluorescence Allow for Confidence when Skin Grafting



36-year-old man with numerous orthopedic trauma injuries developed a wound along ulnar aspect of proximal forearm. Clinicians determined that a skin graft was required, which is contraindicated when a wound is contaminated. Real-time fluorescence images were negative for bacterial fluorescence. Skin graft was therefore applied with confidence within 36 hours. Swabs confirmed no growth of bacteria.

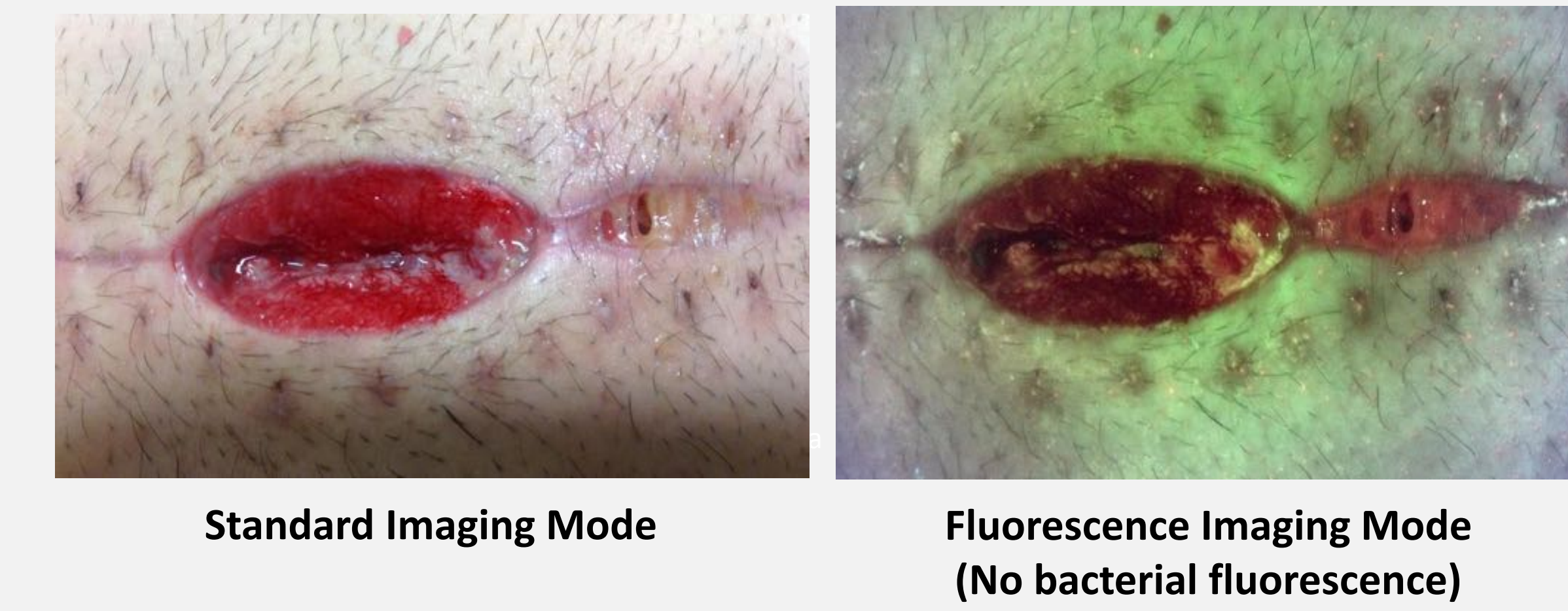
### Images Negative for Bacterial Fluorescence Facilitate Reassurance in High Anxiety Patient



60-year-old female with surgical site infection (heavy growth of *Morganella morganii*) post total abdominal hysterectomy undergoing negative pressure wound therapy (NPWT). Patient had high anxiety requiring anxiety medication at dressing changes. Bacterial fluorescence images were acquired at each NPWT dressing change and demonstrated to the patient that bacterial presence was not increasing.

Patient demanded fluorescence images be acquired at all dressing changes and said, "You have no idea what kind of relief you've given me after shining your light".

### Imaging Negative for Bacterial Fluorescence Guide Antimicrobial Stewardship



57-year-old male with gastric cancer, prescribed systemic antibiotic after partial gastrectomy. Presented with midline dehiscence, antibiotics maintained. Returned when antibiotics were to conclude concerned that midline was opening. Fluorescence images showed no evidence of contamination. These images prevented prescription of further antibiotics.

At two week follow up patient's wound was almost closed.

## CONCLUSIONS

Positive effects of bacterial fluorescence imaging on patient care and wound management were noted in six areas:

- Guided the extent and location of wound debridement, sparing non-contaminated tissue;
- Led clinicians to swab wounds which had otherwise been considered in balance. Targeted sampling of fluorescence-positive regions resulted in moderate/heavy growth of one or more pathogenic bacterial species from all swabs, eliminating risk of false negatives;
- Prevented imminent discharge of three patients requiring systemic antibiotics;
- Guided selection of antimicrobials and directly influenced antimicrobial stewardship practices;
- Facilitated patient education on bacterial presence and provided patient reassurance;
- Images negative for bacterial fluorescence allowed for confidence when skin grafting.

- These results highlight the ability of bacterial fluorescence imaging to provide invaluable, real-time information on a wound's bioburden, contributing to clinician treatment decisions in cases where bacterial contamination could impede wound healing and in cases where bacterial fluorescence was not present.

## REFERENCES

- Bowler PG et al, Wound microbiology and associated approaches to wound management. Clinical Microbiology, 2001.
- DaCosta RS et al. Point-of-Care Auto-fluorescence Imaging for Real-Time Sampling and Treatment Guidance of Bioburden in Chronic Wounds: First-in-Human Results, PLoS ONE 10(3), 2015.
- Wu YC et al. Handheld fluorescence imaging device detects subclinical wound infection in an asymptomatic patient with chronic diabetic foot ulcer: a case report. International Wound Journal, 2015.
- Ottolino-Perry et al. Improved detection of wound bacteria using autofluorescence image-guided wound sampling in diabetic foot ulcers. International Wound Journal (In revisions).

**Acknowledgement:** The authors are grateful to the Lions Gate Hospital Foundation Women's Giving Circle for making possible the acquisition of this MolecuLight i:X bacterial imaging device. Some financial support to attend this meeting was provided by MolecuLight, Inc.