



Practitioner

Rose Raizman RN-EC, MSc, with over 19 years of experience, leads the Save Our Skin (SOS) team at Scarborough & Rouge Hospital located in Toronto, Canada, to combat pressure ulcers of hospital inpatients. She also oversees the wound care clinic for inpatients and outpatients.



Patient Condition

50 year old male patient with a venous leg ulcer (>1 year) on his left medial ankle. Wound presented with heavy drainage and a MRSA infection that had persisted over many months of care, despite numerous antibiotics and antimicrobials. The patient's wound received regular cleaning, debridement and treatment with negative pressure wound therapy.

Monitoring the Effectiveness of an Antibiotic Against MRSA using the MolecuLight *i:X*[®]

Methicillin resistant *Staphylococcus aureus* (MRSA) infections are difficult to treat with standard types of antibiotics and are therefore more dangerous and more costly to the healthcare system.

Clinical Synopsis:

Although Negative Pressure Wound Therapy (NPWT) had significantly reduced wound size in this non-healing venous leg ulcer, all treatments targeting this MRSA infection had been unsuccessful. This prompted the prescription of a newly available oral antibiotic. After one week of treatment, MolecuLight *i:X* fluorescence images revealed a significant decrease in red fluorescence (indicating bacterial loads of $>10^4$ CFU/g), providing feedback on the effectiveness of the antibiotic.

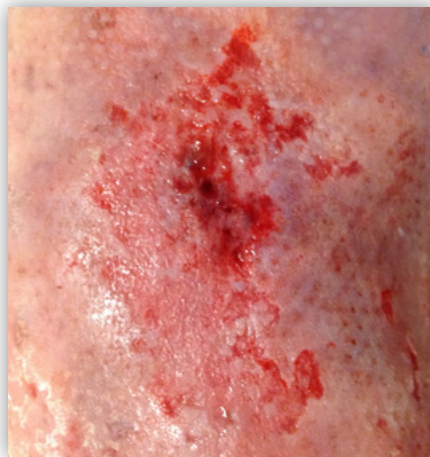

Figure 1: Standard Image.

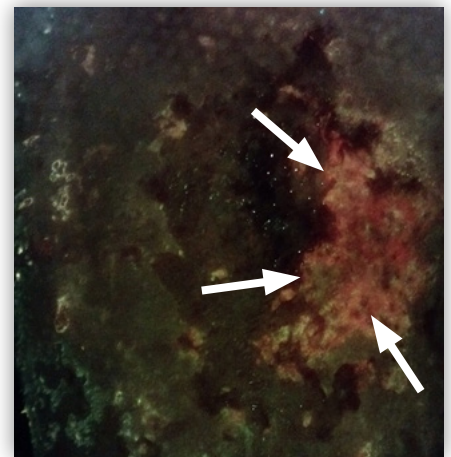


Figure 2: Fluorescence Image. The red color (white arrows) in this fluorescence image suggests the presence of bacterial loads $>10^4$ CFU/g^{1,2}.

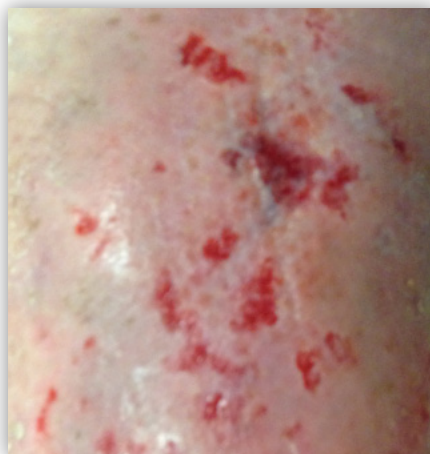

Figure 3: Standard image after one week of treatment.

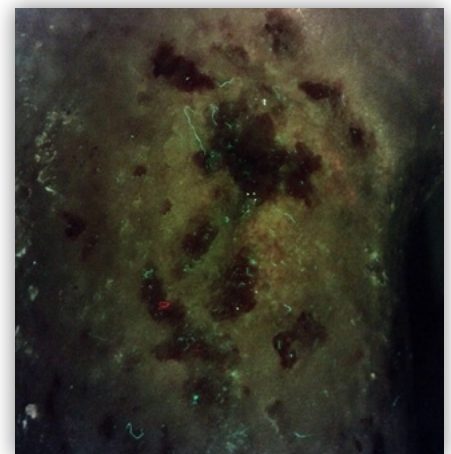


Figure 4: Fluorescence image after one week of treatment with a new antibiotic. The noticeable decrease in red color suggests a significant decrease in bacterial loads to $<10^4$ CFU/g^{1,2}.

MolecuLight *i:X*[®]

The MolecuLight *i:X* allows clinicians to quickly, safely and easily identify wounds with bacteria¹⁻⁴ (at loads of $>10^4$ CFU/g, in combination with CSS) and measure wounds^{2,4} at the point of care to provide them with valuable information to inform treatment and monitor progress^{3,4}.



Testimonial

“I had tried numerous treatments targeting this patient’s MRSA, none of which were effective. The MolecuLight images demonstrated a reduction in bacteria after one week of antibiotic treatment.”

— Rose Raizman RN-EC, MSc

Visit www.moleculight.com

+1.647.362.4684
Toll Free 1.877.818.4360 (Canada)
info@moleculight.com

Follow us:  



References:

1. Rennie MY *et al.* Understanding Real-Time Fluorescence Signals from Bacteria and Wound Tissues Observed with the MolecuLight *i:X*. Diagnostics (2019).
2. Raizman R *et al.* Use of a bacterial fluorescence imaging device: wound measurement, bacterial detection and targeted debridement. J Wound Care (2019).
3. DaCosta RS *et al.* Point-of-care autofluorescence imaging for real-time sampling and treatment guidance of bioburden in chronic wounds: first-in-human results. PLoS One (2015).
4. Cole W & Coe S. The Use of an Advanced Fluorescence Imaging System to Target Wound Debridement, Decrease Bioburden, Improve Healing Rates, and Provide Positive Revenues in an Outpatient Wound Care Setting. Presented at SAWC Fall 2019 (Las Vegas, NV, USA).

©2019 MolecuLight[®] Inc. All Rights Reserved. PN 1386 Rev 1.2

The MolecuLight[®] *i:X* Imaging Device is approved by Health Canada for sale in Canada and has CE marking for sale in the European Union. The MolecuLight[®] *i:X* Imaging Device has received FDA clearance.

MolecuLight[®] is a Registered Trademark in Canada, the US, and the EU.



Red color in this image indicates bacteria ($>10^4$ CFU/g)^{1,2}.